

# OPEN ACCESS ATLAS OF OTOLARYNGOLOGY, HEAD & NECK OPERATIVE SURGERY



## TRANSORAL ROBOTIC OROPHARYNGECTOMY (TORS) SURGICAL TECHNIQUE FOR CANCERS OF TONSIL AND BASE OF TONGUE

Charles D Meyer, Andrew R Larson, Jeremy D Richmon, Andrew J Holcomb

In this chapter the authors describe the use of transoral robotic surgery (TORS) for excision of tonsil and base of tongue (BOT) tumours, including patient selection, pre-operative workup, operative management, and perioperative care.

As of 2015, *The Centers for Disease Control and Prevention (CDC)* reported 18,917 new cases of oropharyngeal cancers (OPSCC) annually<sup>1</sup>. This burden of disease has increased in recent decades with the rapid increase of human papillomavirus (HPV)-associated squamous cell carcinoma (SCC), which is now found in 70% of new cases in the United States of America and Europe<sup>2</sup>. Traditionally, surgical management of OPSCC required either [transoral resection](#) or [open approaches](#), including [suprahyoid \(transhyoid\) pharyngotomy](#), [lip-split mandibulotomy](#) (mandibular swing), or [pull-through techniques](#) that utilise a transcervical visor incision<sup>1</sup>. While these approaches provide excellent surgical access, they may cause significant functional impairment. Advances in radiation therapy and platinum chemotherapeutics led to a preference for radiation-based treatment strategies for OPSCC in the late 1900s<sup>3,4</sup>. However, following this increase in use of nonsurgical therapy, the long-term sequelae of primary radiation and chemoradiation were increasingly appreciated. This inspired exploration of minimally invasive surgical approaches to OPSCC including [transoral laser microsurgery](#) and transoral robotic surgery (TORS).

TORS has since come to be the most utilised surgical approach in much of the developed world for selected patients with OPSCC. Survival and cancer control have been shown to be comparable between TORS and radiation-based treatment strate-

gies for early-stage OPSCC and are generally favorable in HPV-associated disease<sup>5</sup>. Thus, focus has shifted towards treatment morbidity and quality of life. Radiation and chemoradiation are associated with both acute and long-term sequelae including mucositis, fatigue, xerostomia, dysphagia, osteoradionecrosis, cranial neuropathy, and trismus<sup>5,6</sup>. TORS is associated with morbidity as well although of a more acute nature, including pain, swallowing dysfunction, and haemorrhage. Retrospective data have suggested favourable functional outcomes of TORS relative to radiotherapy; yet studies are heterogeneous, and investigation remains ongoing<sup>7</sup>. TORS is also implemented in ongoing treatment deescalation studies that strive to balance minimising treatment-related morbidity with preserving oncologic outcomes.

### Patient Selection<sup>1, 8-11</sup>

Patient selection is the cornerstone of successful TORS practice. Many patients with “resectable” tumours may not be well suited to TORS; thus, a comprehensive understanding of the many factors that contribute to surgical candidacy is paramount for patient selection.

TORS can be employed to resect both benign and malignant disease of the BOT, vallecula, lingual epiglottis, and palatine tonsil, but the most common application is resection of OPSCC. For treatment naïve patients, TORS is well-suited to many of these tumours.

A number of patient, tumour, and contextual factors must be considered when weighing up surgical vs. radiation-based treatment strategies. These are outlined below.

### ***Tumour selection factors***

- **Primary tumour:** TORS is well-suited to T1-2 and selected T3 tumours. Some centers operate on T4a tumours, but more often these are treated nonoperatively. In addition to stage, involvement of specific structures dictates resectability and functional expectations after surgery.

#### ***Relative primary tumour-related contraindications to TORS include:***

- Involvement of >50% of the BOT volume or deep extrinsic muscles. Anterior extension of tumour beyond the hyoid bone in a sagittal plane often indicates deep extension not ideally suited for resection
  - Soft palate involvement requiring resection of >50% of the hemipalate increases risk for postoperative velopharyngeal insufficiency
  - Involvement of skull base, hyoid, great vessels, mandible, prevertebral fascia, pterygoid musculature, or any laryngeal involvement
  - Communication of oropharyngeal cancer with cervical lymphatic disease...increases risk of a large or persistent pharyngocutaneous fistula
- **Nodal disease:** Cervical metastases often affect decisions about adjuvant therapy. Indications for adjuvant therapy continue to evolve and are the subject of ongoing investigation. Patients with <2 lymph nodes without extranodal extension (ENE) on final surgical pathology may be candidates for single-modality surgical therapy with TORS.

#### ***Relative lymph node-related contraindications to TORS include:***

- Clear evidence of ENE on clinical examination (fixation) or on imaging. Note that imaging has poor ac-

curacy in identification of ENE or matted lymphadenopathy

- >4 pathologic lymph nodes visible on imaging: considered a criterion for adjuvant chemoradiation
  - Bilateral pathologic lymphadenopathy on imaging
- **Distant metastasis:** This is a contraindication to surgical therapy of OPSCC, although oligometastatic disease has been treated with curative intent in HPV+ OPSCC

### ***Patient selection factors***

- **Anatomic considerations:** Adequate transoral access is critical to safely perform TORS. Though newer flexible robotic platforms can overcome some challenges with access, ***certain factors may make access challenging*** including:
  - Severe trismus
  - Mallampati score 3-4
  - Prominent incisors
  - Macroglossia
  - Prominent mandibular tori
  - Poor neck extension
  - Retropharyngeal carotid - Increases risk of carotid artery injury with tonsil tumour resections
- **Comorbidities:** Patients who cannot tolerate general anaesthesia are poor candidates for TORS. Patients with bleeding disorders or who cannot pause anticoagulation or antiplatelet therapy should also be considered for non-surgical strategies. Other comorbidities, such as immunodeficiency, diabetes, or malnutrition may complicate both surgical and nonsurgical approaches to oropharyngeal tumours
- **Oncologic history:** Patients with recurrent OPSCC or a history of high dose irradiation to the oropharynx should be

considered for open surgical approaches with vascularised reconstruction, although TORS may be appropriate in selected cases.

- **Contextual factors**
  - **Availability of robotic technology and training:** Robotic surgical platforms or training to safely use it are not universally available. Transoral laser microsurgery remains the preferred transoral approach in many centers and should be considered equivalent to that of TORS as a surgical modality.
  - **Collaboration with radiation and medical oncology physicians:** The decision to perform TORS should be made as part of a multidisciplinary cancer treatment team. A mutual understanding of indications for adjuvant therapy after TORS prior to selection of primary treatment may minimise use of trimodality therapy or unnecessary adjuvant radiotherapy.

## Preoperative Evaluation

Comprehensive evaluation is critical for patient selection and to optimise surgical outcomes. This process is inherently multidisciplinary, so forming an effective team is highly beneficial.

**History:** Many patients may be asymptomatic and present only with a neck mass or tonsil asymmetry. A complete history of the present illness identifies symptoms which may be nonspecific, including sore throat, changes in swallowing or voice, asymmetric otalgia, or unintended weight loss. Past medical and surgical history, especially of previous surgical or radiation treatment to the head and neck, is useful to assess surgical candidacy, as is assessment of functional status.

**Physical exam:** A complete head and neck exam identifies the location and extent of the primary tumour and lymphadenopathy. Oral cavity exam will identify anatomic challenges to surgery such as trismus and will assess dentition and possible need for dental rehabilitation or extraction prior to radiotherapy. Cranial nerve exam should identify hypoglossal nerve involvement by deeply invasive tumours, or spinal accessory nerve involvement by lymphadenopathy.

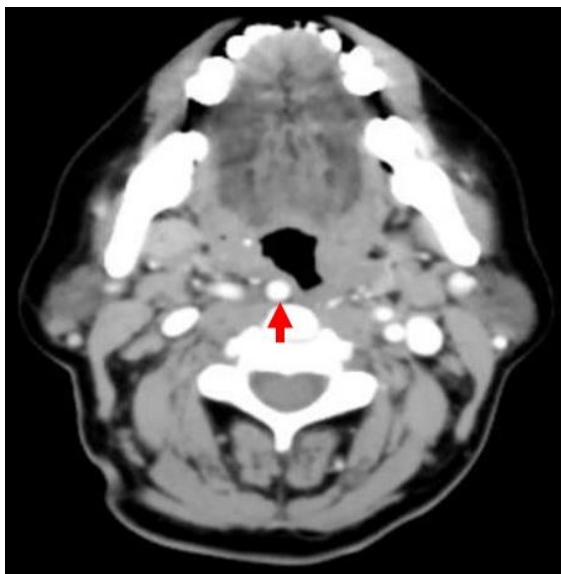
**Flexible fiberoptic laryngoscopy:** This provides a more detailed exam compared to mirror exam and allows for photo or video documentation for treatment conference discussion or future reference. Many HPV-related cancers present as an [unknown primary](#), and a high-definition evaluation may be critical to identify subtle vascular and mucosal abnormalities associated with such occult lesions.

**Biopsy with/without operative laryngoscopy:** Tonsil tumours may be amenable to in-office transoral biopsy, and if well-defined and palpable, a separate operative laryngoscopy may be avoided in selected cases. Operative laryngoscopy is often an essential aspect of patient evaluation and allows for further evaluation of tumour extent (especially deep extension), surgical exposure, and to exclude second primary tumours. If nodal disease is present, fine needle aspirate cytology, optimally with ultrasound guidance, may aid diagnosis or treatment planning. Pathology specimens should be evaluated for p16 and/or high-risk human papillomavirus status to guide staging and treatment.

**Neck imaging:** Computed tomography (CT) or magnetic resonance imaging (MRI) may be used to image the primary tumour and at-risk nodal basins. MRI is preferred to identify pterygoid muscles, parapharyngeal space, perineural invasion, and deep tongue muscle involvement and may be superior in the setting of significant dental repair arti-

fact but is more expensive and less readily available. Ultrasound may complement but should not replace cross-sectional imaging of neck disease.

Special attention should be paid to the location and course of the *internal carotid artery (ICA)*. Its location can vary with age, progressively moving laterally, from 1.4 cm from the most medial portion of the muscular aspect of the tonsillar fossa in a 1-year-old, to 2.5 cm in an adult <sup>1</sup>. However, 2-3% of the population have variations that displace the ICA towards the retropharynx. A retropharyngeal carotid artery may significantly increase the risk of intraoperative injury, especially with tonsil tumour resection (*Figure 1*).



*Figure 1: Retropharyngeal carotid artery*

**Systemic imaging:** Whole-body positron emission tomography (PET) provides a comprehensive systemic evaluation with excellent sensitivity. If unavailable or in lower-risk scenarios (smaller tumours, low nodal disease burden), CT chest is sufficient to exclude lung metastasis, the most common distant metastatic site.

**Swallow evaluation:** Patients should be informed of the effects of surgery and of non-surgical treatments on swallowing func-

tion. Speech Language Pathology (SLP) evaluation prior to oropharyngectomy can assess the patient's current function, provide strategies for swallow optimisation, and set reasonable expectations for recovery.

**Multidisciplinary evaluation(s):** Patients should be fully informed of all available treatment options and their associated risks and benefits. This may involve pre-treatment consultations with medical oncology and/or radiation oncology. Ideally, patients should be discussed in a multidisciplinary setting, both to foster discussion of the optimal primary treatment strategy and to discuss possible indications for adjuvant therapy. Other multidisciplinary referrals may include social work, prosthodontics/ dental oncology, palliative care, and mental health. By establishing these relationships preoperatively, patients are better informed and better prepared to manage the significant stress and challenges associated with their cancer management.

**Preanaesthetic evaluation:** An assessment of the patient's fitness for general anaesthesia is mandatory.

### **Surgical Anatomy** <sup>1, 12, 13</sup>

Failure to understand transoral surgical anatomy from an "inside-out" approach is a common cause of surgical errors.

### **Palatine Tonsils**

- **Boundaries:** Palatoglossus muscle anteriorly, palatopharyngeus muscle posteriorly, confluence of tonsillar pillars and soft palate superiorly, glossotonsillar sulcus inferiorly, and superior and middle constrictor muscles laterally (*Figures 2 - 4*). The buccopharyngeal fascia is a thin areolar plane that separates the constrictor muscles from the parapharyngeal fat and therefore repre-

sents the true lateral border of the space. Inferiorly the styloglossus and stylopharyngeus form a deep lateral border (Figure 5).

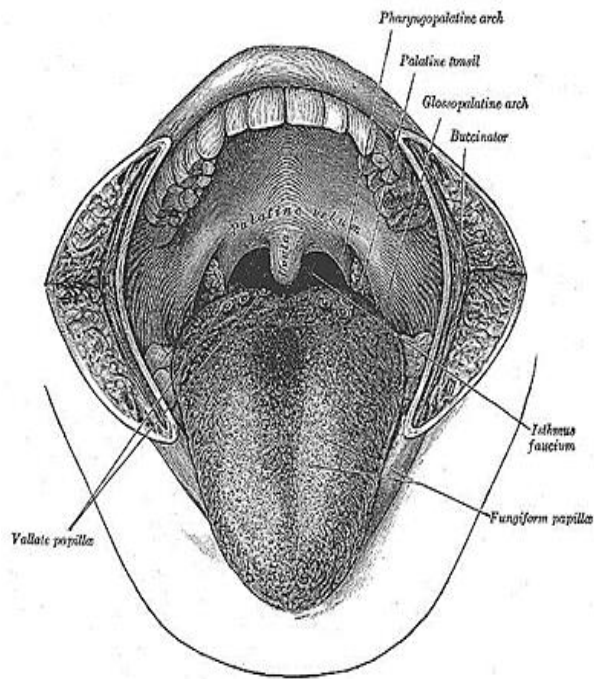


Figure 2: Topography of anterior tongue

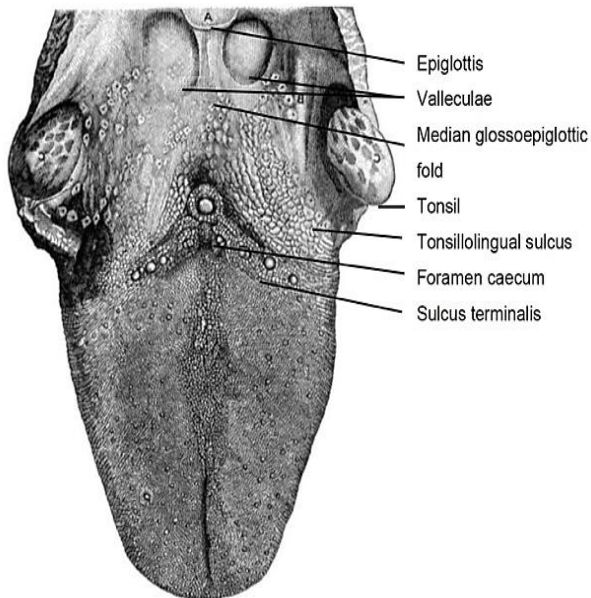


Figure 3: Superior topography of tongue

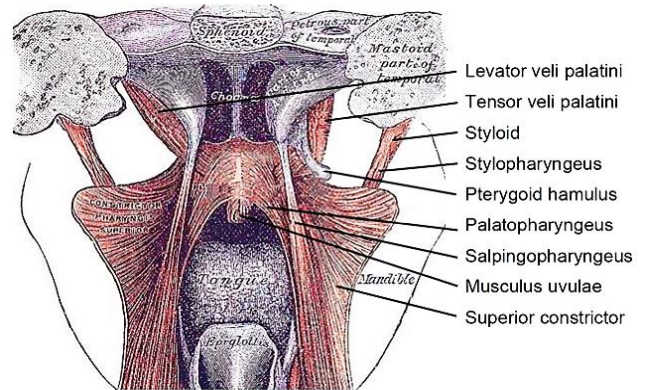


Figure 4: Muscles of the soft palate

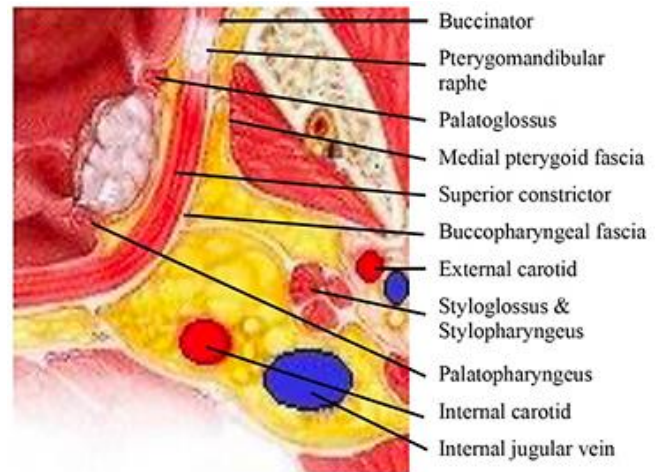


Figure 5: Lateral pharyngeal wall anatomy

• **Blood supply**

- Tonsillar branch of ascending pharyngeal artery, descending palatine artery branches, tonsillar branch of facial artery, dorsal lingual artery, ascending palatine artery. (Figure 6). The primary arterial supply is from the tonsillar branch of the facial artery, which enters the tonsillar fossa from inferomedial as it passes through the superior constrictor muscle
- Venous drainage is to facial and retromandibular veins, and then into internal jugular system

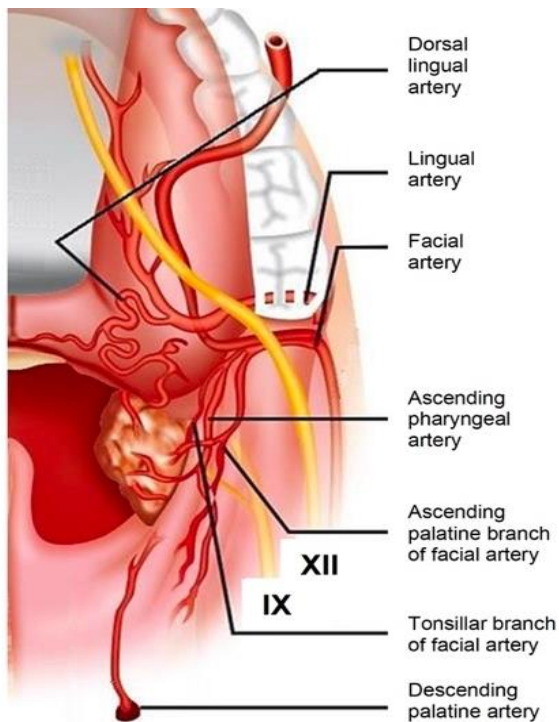


Figure 6: Blood supply to the tonsil

- **Innervation**

- **Glossopharyngeal nerve and pharyngeal plexus** (Sensory/motor)
- The glossopharyngeal nerve is commonly sacrificed during oropharyngeal resection
- It travels inferiorly from the jugular foramen, passes between the internal jugular vein (IJV) and ICA, then continues anteriorly to the ICA. It passes deep to the stylopharyngeus muscle and then enters the pharynx between the superior and middle constrictors. It is here, as it enters the pharynx at the posteroinferior aspect of the tonsil fossa that it is at greatest risk of injury either directly, or from stretch or thermal injury.
- The stylopharyngeus and styloglossus muscles and stylohyoid ligament pass between the middle and superior constrictors, traveling from superolateral to inferomedial, to enter the pharynx near the base of the palatine tonsil. The glossopharynx-

geal nerve travels between and lateral to the stylohyoid ligament and styloglossus muscle at this level. Therefore, identification of these structures can help protect the glossopharyngeal nerve from injury. (Figure 7)

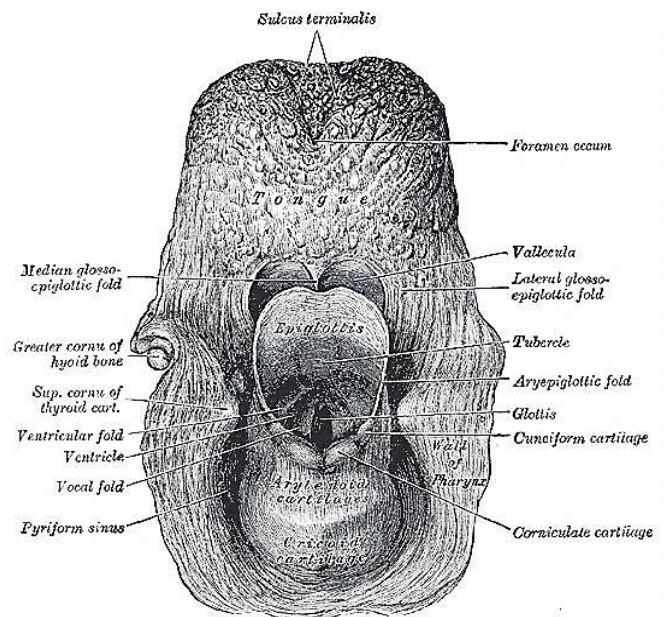


Figure 7: Topographical anatomy of BOT

- The *submandibular gland* is located lateral to the styloglossus muscle and may be encountered during a radical tonsillectomy once the superior constrictor is resected. If encountered, there is a higher risk of communication between the oropharynx and the neck if a neck dissection (including Level Ib) or vascular ligation is to be performed concurrently.

### Base of Tongue

- **Blood supply**

- The *lingual artery* (Figures 8, 9) branches from the external carotid artery (ECA) at the level of the greater horn of the hyoid bone,

travels laterally to the middle constrictor muscle and deep to the hyoglossus muscle. It then runs anteriorly along the superior aspect of the hyoid bone and provides the suprahyoid, dorsal lingual, and sublingual arteries, and the *arteria profunda linguae*. It is most vulnerable to injury during BOT surgery as it passes under the hyoglossus muscle. The dorsal branch will frequently need to be identified and ligated with BOT tumours, but the main lingual artery can either be preserved or prophylactically ligated during neck dissection to decrease risk of postoperative bleeding. The lingual artery may also anastomose with the contralateral lingual artery system

- **Venous drainage** is to the facial and retromandibular veins, and then into the internal jugular system

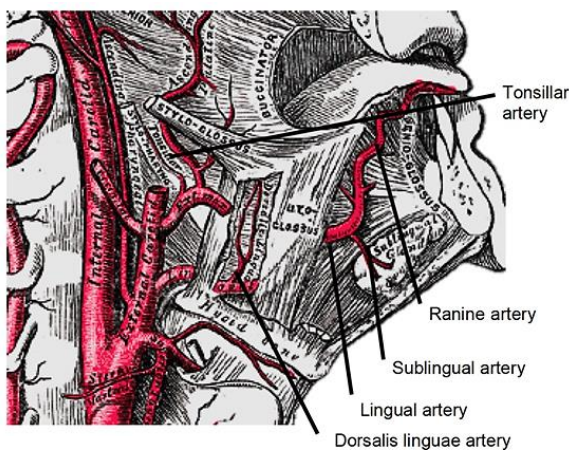


Figure 8: Lingual artery

- **Innervation**
  - Sensory: Lingual branch of glossopharyngeal nerve
  - Motor: Hypoglossal nerve (Figure 9). During posterolateral dissection of the BOT, the hypoglossal nerve is at risk where it travels over the hyoglossus muscle and along the

superior aspect of the hyoid bone, although it is rarely injured.

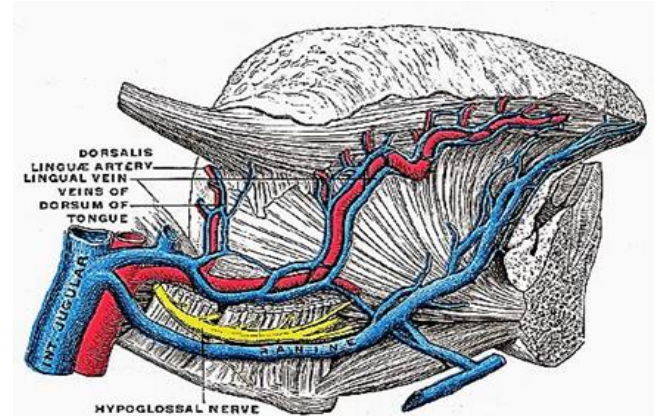


Figure 9: Hypoglossal nerve and lingual artery

## Instrumentation and Setup

For detailed information and photos on room setup, exposure, and instrumentation for TORS, refer to the separate chapter "[Transoral Robotic Surgery \(TORS\): Setup and Basics](#)".

## Surgical Technique

### 1. Patient positioning and preparation

- Position the bed to allow the patient cart to be appropriately stationed next to the patient
- Place the patient in a supine position
- Intubation may be done transorally or transnasally. Transnasal intubation is often advantageous in BOT tumours, whereas transoral intubation is acceptable in tonsillar dissections
- Secure the endotracheal tube with tape or a suture
- Place eye protection. Durable eye shields reduce the risk of ocular injury

### 2. Exam under anaesthesia

- Visually inspect and palpate the oropharynx to define the tumour ex-

tent and to identify second primary tumours

- Operative laryngoscopes may be necessary to fully evaluate tumour extent
- Palpation is an important way to assess deep extension. A fixed tumour may indicate involvement of medial pterygoid or deep tongue muscles which is a contraindication to TORS

### 3. Oral suspension

- Expose the oral cavity with a Crowe-Davis, Dingman, Medrobotics Flex, or FK-WO retractor (Figures 10 – 13)
- Suspend the retractor with a Mayo stand or suspension arm (Figure 14)

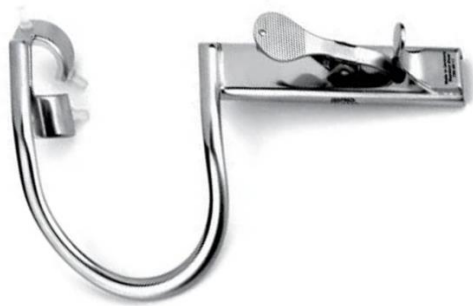

Figure 10: Crowe-Davis retractor (without tongue blades)

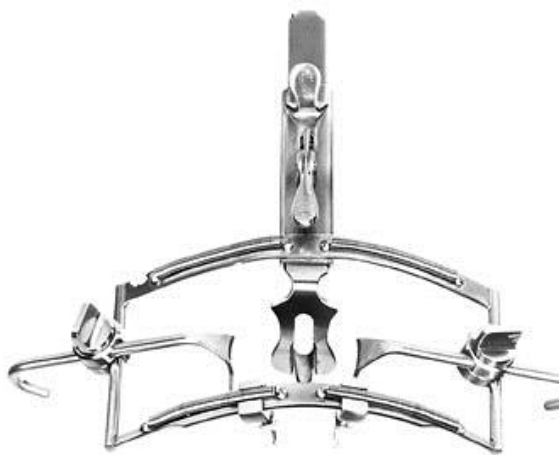

Figure 11: Dingman retractor

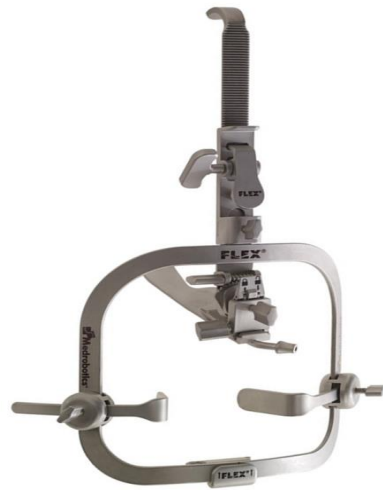

Figure 12: Medrobotics Flex



Figure 13: FK-WO retractor

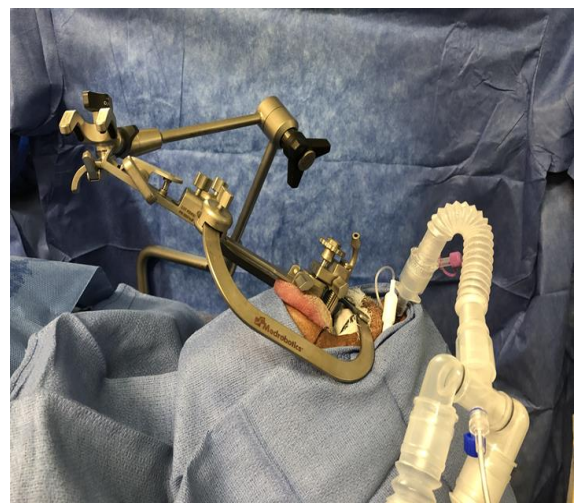

Figure 14: Patient undergoing TORS in suspension using the Medrobotics Flex® retraction system



- Passing a horizontal mattress silk suture through the anterior tongue may be helpful for retraction and tongue manipulation, especially in BOT tumours

#### 4. Robot docking

- Once adequate suspension and tumour visualisation are achieved, the robot is docked transorally
- The da Vinci Si or Xi robotic platform (Intuitive Surgical Systems, Sunnyvale, CA, USA) is currently the only robotic surgical system in the USA approved for TORS
- 0-degree cameras are generally best for tonsil tumours and 30-degree for BOT
- Flexible robotic systems offer fully wristed cameras
- The Maryland dissector and monopolar cautery are commonly used robotic instruments (*Figures 15, 16b*)



*Figure 15: Maryland dissector*

- The da Vinci SP offers a wide array of additional instruments, including scissors and bipolar cautery
- The monopolar cautery is typically positioned ipsilateral to the tumour
- Care should be taken that the robotic arms are positioned to minimize interference with each other and oral cavity structures

#### 5. Assistant surgeon

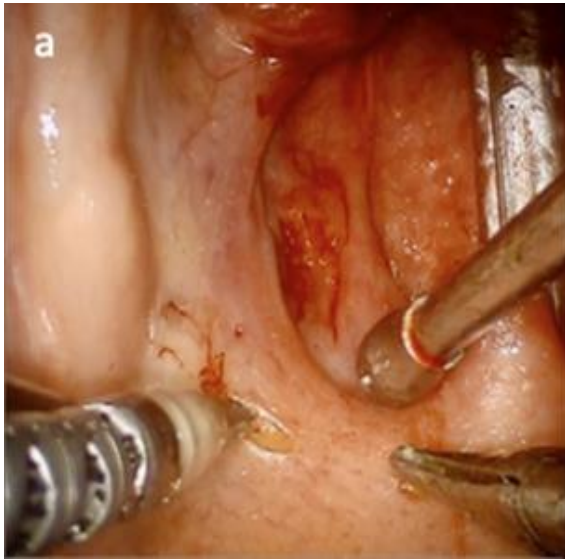
- Should be positioned to easily see the display on the vision cart and be able to clearly hear the primary surgeon either through the integrated communication console or directly in the operating room
- Has an essential role to suction smoke, maintain haemostasis, and provide tension/ counter tension and exposure
- Yankauer suction catheters and Hurd retractors are commonly used to provide tensional forces (*Figures 16a-c*)
- Endoscopic surgical clips and suction monopolar electrocautery are essential for haemostasis

#### Tonsil tumour dissection

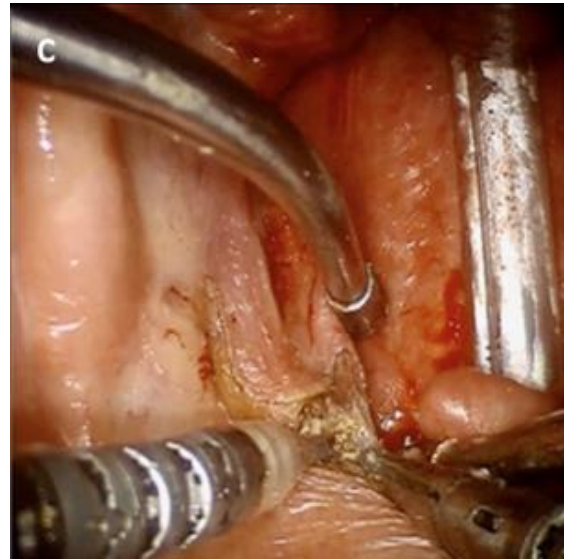
The following description is of a classic *en-bloc* lateral oropharyngectomy. However, the amount of tissue resected is tailored to the tumour size. The sequence of the operative steps is dictated by specifics of the patient's anatomy and tumour as well surgical expertise.

##### 1. Superior and lateral mucosal incisions

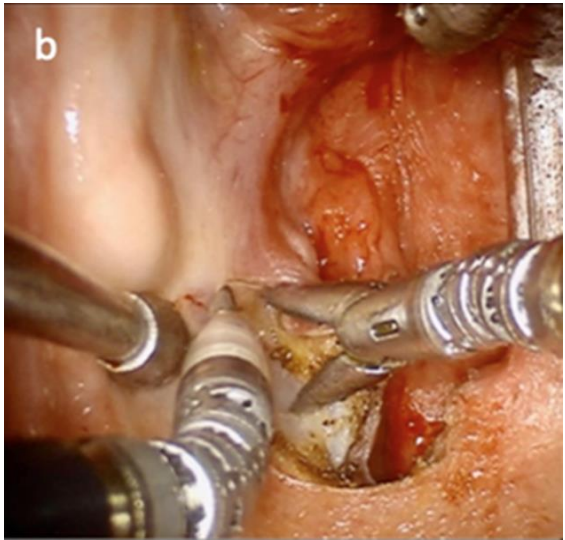
- Make initial mucosal incisions superiorly (*Figure 16a*) and laterally (*Figure 16b*) and proceed in an inferomedial direction. The superior incision involves a cuff of soft palate mucosa, and the lateral extension passes along the pterygomandibular raphe
- Some surgeons initially make mucosal cuts circumferentially around the tumour to prevent them becoming disoriented during the dissection



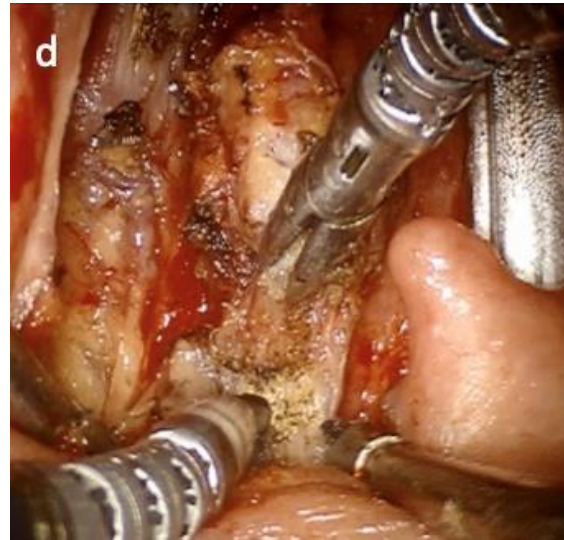
*Figure 16a: Superior soft palate mucosal incision*



*Figures 16c: Transection of superior muscular attachments*



*Figure 16b: Lateral mucosal incision at pterygomandibular raphe*

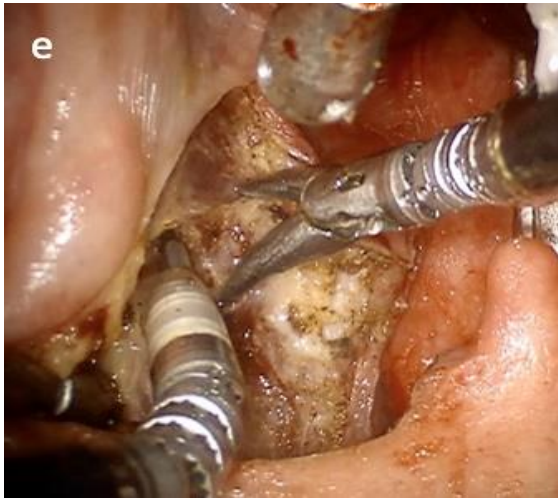


*Figures 16d: Release of superior constrictor muscle superiorly*

## **2. Submucosal muscle dissection**

- Carry the dissection through the superior attachments of the palatoglossus, palatopharyngeus and finally the superior constrictor muscles (*Figures 16c - d*)

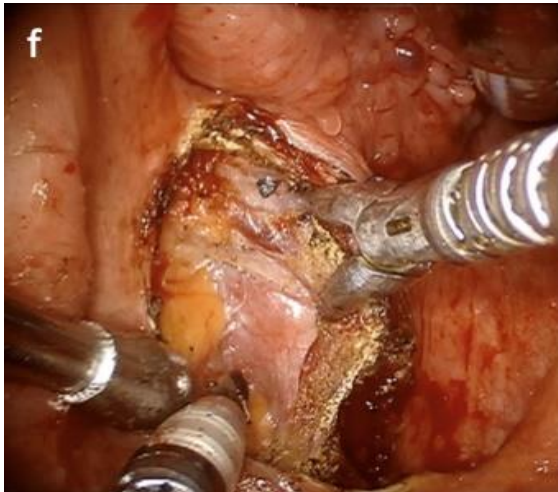
- Laterally, develop the plane between the superior constrictor and medial pterygoid muscles (*Figure 16e*)



*Figure 16e: Lateral dissection plane between superior constrictor and medial pterygoid muscles*

### 3. Buccopharyngeal fascia dissection

- Once through the muscular layers, the medial pterygoid muscle and buccopharyngeal fascia should be in view (*Figure 16f*)



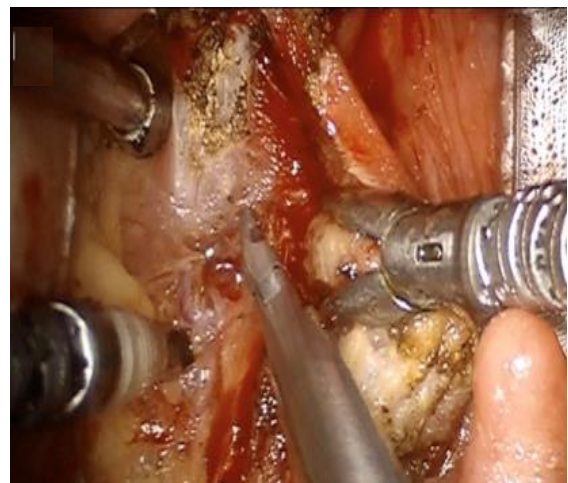
*Figures 16f: Pterygoid muscle and buccopharyngeal fascia in view*

- The buccopharyngeal fascia defines the lateral extent of the dissection and should not be violated, if possible, to minimise risk of injury to the internal carotid artery

- The dissection may also be performed in a “muscle splitting” fashion whereby a thin layer of constrictor muscle is left intact laterally to limit PPS dissection
- Continue the dissection in this plane in an inferomedial direction, using the contralateral Maryland retractor to maintain continuous, but gentle traction

### 4. Control of pharyngeal vessels

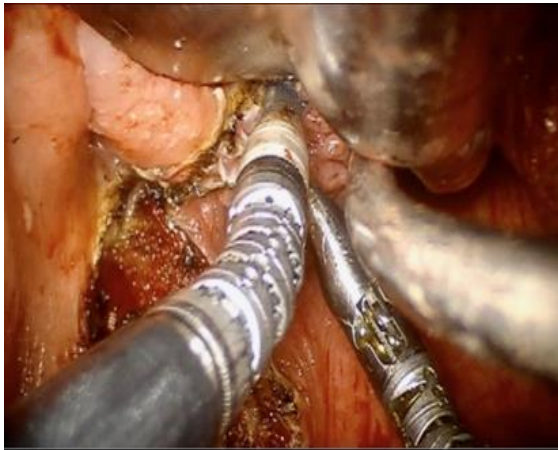
- Once the parapharyngeal fat comes into view through the buccopharyngeal fascia, ICA pulsations can frequently be seen
- During this part of the dissection, it may be necessary to identify and ligate the tonsillar branch of the lesser palatine artery and vein superiorly, then the tonsillar branches of the ascending pharyngeal and ascending palatine arteries more inferiorly. These should be ligated with surgical endoclips on both the patient and tumour sides (*Figure 17*), preferably applying multiple clips on the patient side to minimise risk of post-operative haemorrhage.



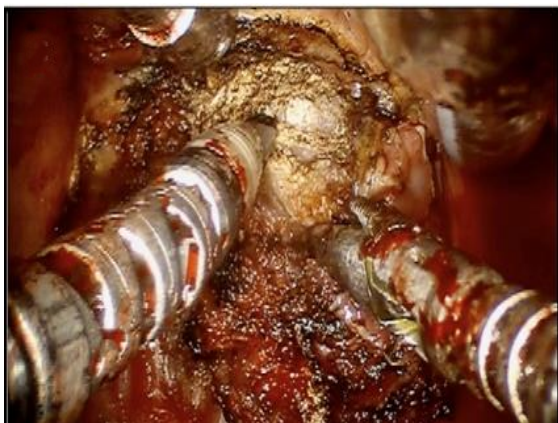*Figure 17: Control of pharyngeal vessels*

## 5. Inferior mucosal incisions

- Include a cuff of BOT if needed for adequate margin clearance (*Figure 18*)
- This mucosal incision is best accomplished before the tumour rotates out of its anatomic position
- Carry the dissection to a depth of 1-2cm through the base of tongue muscle to ensure an adequate soft tissue margin (*Figure 19*)



*Figure 18: Base of tongue incision*



*Figure 19: Base of musculature incised*

## 6. Inferior muscle incision

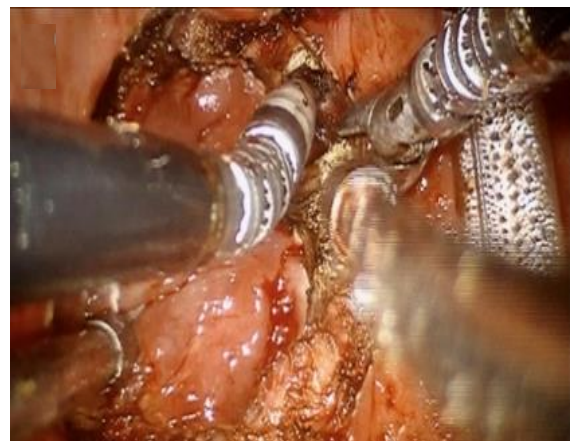
- Rotate the tumor medially or laterally to expose and place on tension on the tumour and divide the inferior attachments of the pharyngeal

constrictors, styloglossus and stylopharyngeus muscles

- It is at this point that the glosso-pharyngeal nerve and dorsal lingual artery are most at risk
- Identifying and preserving the stylohyoid ligament can help prevent injury to the nerve, which is reliably found deep and lateral to the ligament
- The styloglossus and stylopharyngeus may need to be resected to a variable extent depending on the depth of the tumour

## 7. Posterior pharyngeal wall incision

- Retract the tumour medially and dissect it off prevertebral fascia
- The extent of posterior pharyngeal wall dissection is defined by the tumour
- Free the constrictor muscles from their medial attachments (*Figure 20*)
- Remove the specimen



*Figure 20: Releasing medial attachments of pharyngeal constrictor muscles*

## BOT tumour dissection

The dissection is similar to that of tonsillar tumours. The patient's anatomy and tumour

dictate the order of surgical steps, as do the surgeon's comfort and training.

### 1. Anterior mucosal incision

- The initial mucosal incision may be performed transversely just behind the retractor
- Deepen this incision through the muscle, taking care to angle the cutting instrument anteroinferiorly to avoid cutting towards tumour (Figure 21)
- This incision is made without retraction to a depth of approx. 1cm
- At this point the Maryland dissector can be used to provide traction on the specimen

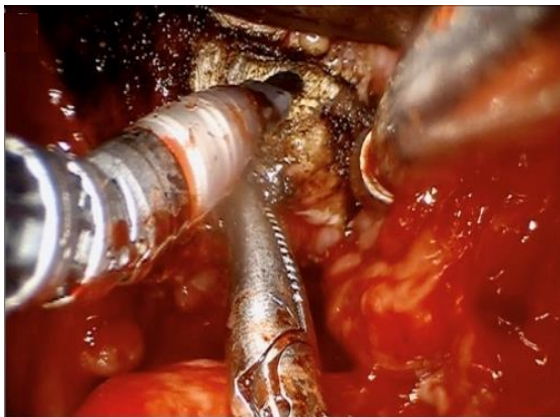


Figure 21: Initial transverse incision into base of tongue

### 2. Medial incision

- Make a 2<sup>nd</sup> medial incision through BOT mucosa from anterior to posterior until the vallecula is reached (Figures 22,23)
- Carry this incision through the muscle with care not to angle toward the tumour. This permits proper assessment of specimen depth

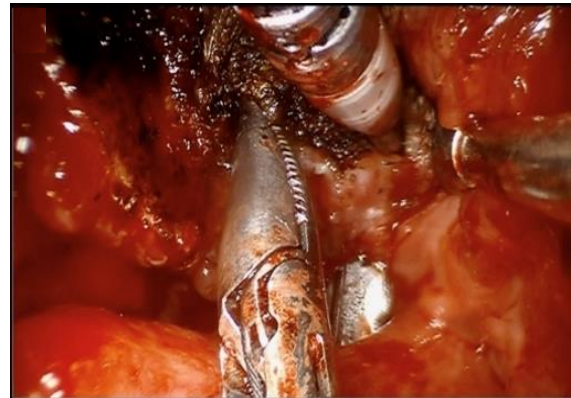


Figure 22: Medial incision into base of tongue

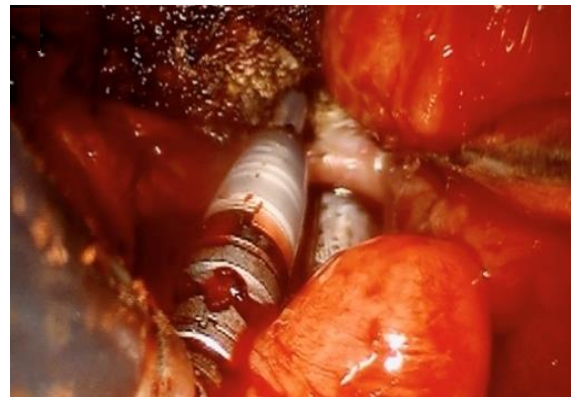


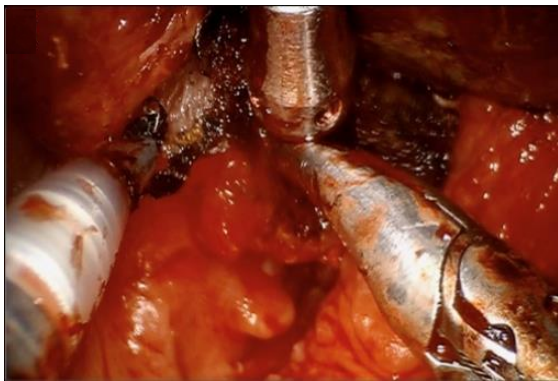
Figure 23: BOT incision continued posteriorly into vallecula

### 3. Lateral incision

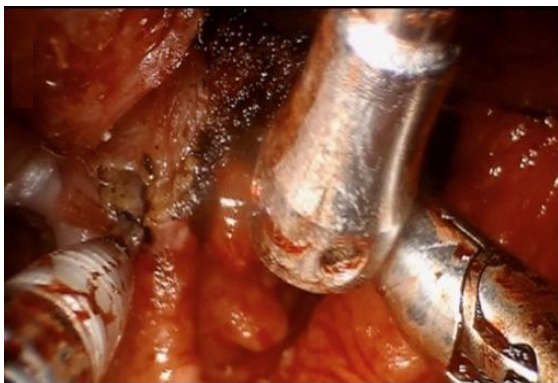- The remainder of the dissection proceeds in lateral-to-medial
- Continue the mucosal incision across the glossotonsillar sulcus (Figure 24) and pterygomandibular raphe (Figure 25)
- Continue along the lateral pharyngeal wall up to the vallecula (Figures 26,27)
- This approach allows for better assessment of depth than a purely anterior-posterior approach
- As the specimen is progressively medialised, incise the intrinsic tongue muscles in a crescentic fashion to allow the tumour specimen to be

medialised in a balanced fashion rather than being twisted

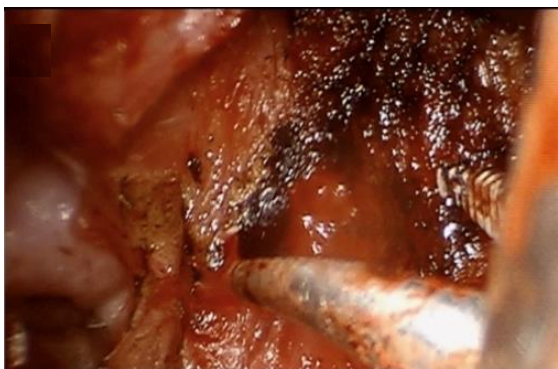
- Assess the tumour margins frequently to assure that the tumour is not violated



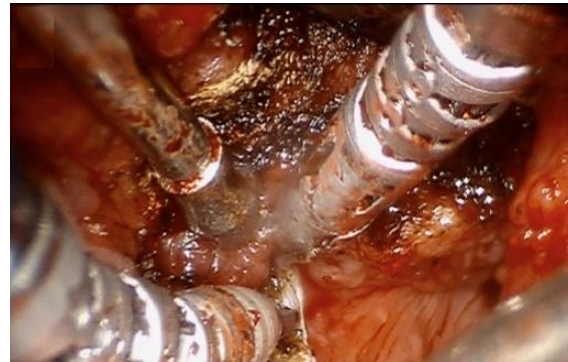
*Figure 24: Initial lateral incision of base of tongue in glossotonsillar sulcus*



*Figure 25: Lateral dissection along pterygomandibular raphe*

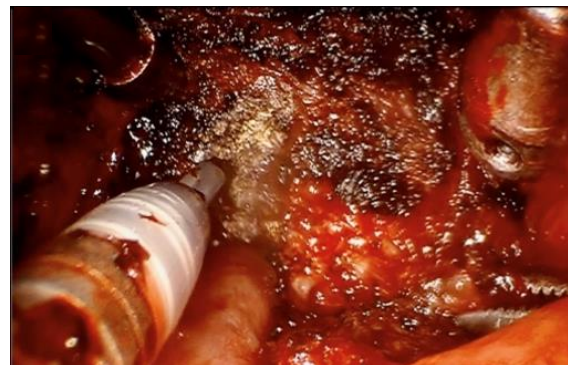

*Figure 26: Lateral dissection along pharyngeal wall*

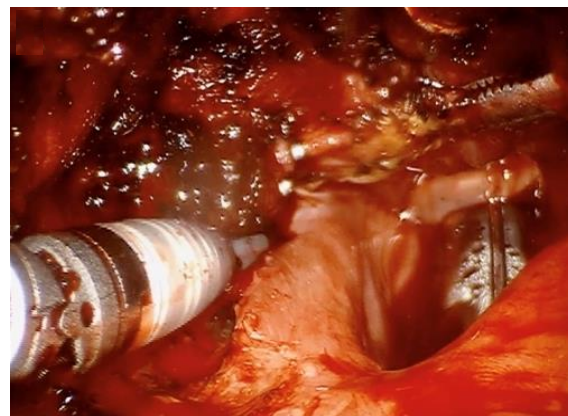

*Figure 27: Continuing dissection into lateral vallecula*

- Tongue muscle is easily identified by its elastic qualities that are absent in tumour tissue (*Figure 28*)
- The lingual and dorsal lingual arteries enter laterally and should be anticipated and controlled as needed with surgical clips when encountered (*Figure 29*)



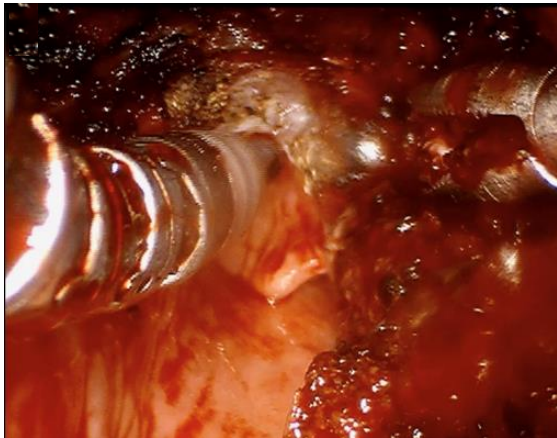
*Figure 28: Deep dissection of tongue*



*Figure 29: Lingual and dorsal lingual arteries ligated with surgical clips*

#### 4. Vallecular incision

- The final incision releases the mucosa of the vallecula and frees the specimen (*Figure 30*)
- The tumour often needs to be retracted anteriorly to avoid injury to the epiglottis during this mucosal release



*Figure 30: Final incision releases mucosa of vallecula to free the tumour*

#### 5. Specimen orientation

- It is critical to clearly understand the tumour orientation prior to completing the mucosal incisions, as the specimen is easy to disorient, especially in BOT tumours
- The console surgeon and assistant should have a clear mutual understanding of the specimen orientation before the tumour is retrieved from the oral cavity by the assistant
- This process may be aided by “replacing” the tumour in the surgical defect and marking the most superior or lateral margin with a suture, clip or marking ink

#### 6. Haemostasis

- Irrigate and inspect the tumour bed for bleeding

- Monopolar or bipolar cautery is appropriate for smaller vessels
- Surgical clips are used for larger or named vessels
- Valsalva manoeuvres may aid to identify at-risk areas for bleeding

#### Operative Decision Making

**Neck Dissection:** Elective neck dissection is generally indicated for all primarily surgically managed OPSCC due to high rates of lymphatic metastasis. Neck dissection may be performed concurrent with TORS or in a separate setting. Concurrent neck dissection allows for vascular ligation of the external carotid artery branches in the neck to minimise risk of bleeding, and avoids multiple surgeries, reduces cost, and narrows the recovery interval for progression to adjuvant therapy if needed. Staging the primary tumour resection after neck dissection minimises risk of a pharyngocutaneous fistula and provides pathologic information, including the number of lymph nodes metastases and presence of extranodal extension that may select patients for nonsurgical treatment of the primary tumour. Limitations to access to robotic surgery may also necessitate a staged neck dissection in some practice settings.

**Vascular Ligation:** Ligating branches of the external carotid artery during neck dissection is a common practice and decreases rates of catastrophic postoperative haemorrhage<sup>14, 15</sup>. Lingual, facial, superior laryngeal, and ascending pharyngeal vessels are commonly ligated. Some surgeons prefer to ligate the external carotid artery, though ligating the ascending pharyngeal artery may predispose the patient to first bite syndrome.

**Reconstruction after TORS:** Most TORS radical tonsillectomy or BOT defects heal by secondary intention. More complex closure techniques have been described, inclu-

ding local, regional, and free flaps. Of-ten a fibrin-based sealant (e.g., VistaSeal) is placed in the wound to reduce postoperative pain and decrease risk of minor bleeding. In the setting of salvage oropharyngectomy with TORS, the authors have a low threshold for reconstruction with vascularised tissue to cover irradiated vasculature.

## **Perioperative Management**

Most perioperative practices are based on low-level data or data extrapolated from treatment of other surgical patients rather than TORS patients. The following are common practices:

### ***Airway management***

- Transoral intubation is appropriate in many patients, especially tonsil tumours
- Transnasal intubation has the advantage of moving the endotracheal tube (ETT) out of the oral cavity and improving visualisation of the oral tongue and tongue base
- Tracheostomy may be considered for select patients especially in salvage settings or when there is higher risk of haemorrhage
- Airway fire is a high risk. Therefore, fraction of inspired oxygen (FiO<sub>2</sub>) should be kept below 30% and surgeons may consider using a reinforced or laser safe endotracheal tube

***Antibiotics:*** Recommendations for clean-contaminated head and neck surgery should be followed e.g., ampicillin-sulbactam, or a combination of cefazolin and metronidazole. Clindamycin can be used for penicillin allergic patients. Continuation of antibiotics for only 24hours in the postoperative period is supported by data in clean-contaminated surgery.

***Steroids:*** Intraoperative 8-12mg intravenous dexamethasone is commonly used and

is continued for 24hours while an inpatient with or without an oral steroid taper at discharge, as it may decrease airway oedema and improve postoperative pain control in appropriately selected patients.

***Diet:*** Most patients tolerate an oral diet by hospital discharge. Evaluation by speech language pathology (SLP) with counseling on swallowing function is beneficial. With close coordination with the SLP service, patients are assessed on postoperative day 1 for diet initiation. Some patients need temporary placement of a nasogastric feeding tube, although this is very uncommon in the authors' practice<sup>16</sup>. Some surgeons choose to place nasogastric feeding tubes intra-operatively and to remove them when no longer needed; others place them postoperatively only in patients with compromised swallowing. Feeding tubes are also more commonly necessary with salvage surgery, when free flaps are used, or if an intra-operative fistula is created. A minority of patients require gastrostomy tube placement; this is most often needed during adjuvant therapy.

***Oral hygiene:*** Patients are counseled about oral hygiene, as fungal or bacterial overgrowth are common in patients undergoing TORS. Chlorhexidine or saline mouth rinses with meals are often appropriate, and normal brushing and flossing activity is usually permissible in the postoperative period.

***Pain management: Oropharyngectomy is a painful procedure,*** and patients should be counseled about postoperative pain expectations. Multimodal analgesia is an effective way to minimise reliance on opiates and to provide effective pain relief. Tylenol (Acetaminophen) and ibuprofen are effective, inexpensive, and widely available with an acceptable toxicity profile. Although no studies directly address safety of ibuprofen in TORS patients, has been extensively



studied in tonsillectomy patients and has not been found to increase bleeding. The authors generally commence ibuprofen on postoperative day 3. COX-2 inhibitors such as celecoxib are an alternative to ibuprofen and are likely to carry a lower risk of bleeding. Opiates are typically included in multimodal analgesia regimens. Neuropathic pain agents such as gabapentin are used in some settings. Topical analgesics such as lidocaine may also benefit patients but should be balanced against the risk of aspiration especially in patients with already impaired sensation such as those with glossopharyngeal nerve injury.

***Venous thromboembolism (VTE) prophylaxis:*** No studies directly report risks and benefits of VTE prophylaxis in TORS. While prevalence of VTE is low in otolaryngology relative to other surgical specialties, many patients with oropharyngeal cancer are at risk for VTE and could benefit from VTE prophylaxis. Ultimately, this should be based on individual patient and surgical factors and to balance risks of VTE with postoperative haemorrhage.

### **Surgical Complications and Pitfalls**

***Haemorrhage:*** Postoperative bleeding occurs in 3-8% of patients and may cause aspiration or exsanguination if not rapidly recognised and addressed. Bleeding may occur from the ***dorsal lingual artery*** as it enters the base of tongue, or from the ***tonsillar branch of the facial artery*** as it enters the base of the tonsillar fossa (*Figure 6*). The ***main trunk of the lingual artery*** can also be encountered during deeper dissection at the level of the hyoid bone and hyoglossus muscle

***Pharyngotomy:*** A communication between the oropharyngeal dissection and the neck compartment frequently occurs at the glossotonsillar sulcus. Its development is of greater concern when a concurrent neck dis-

section is performed. Preserving the submandibular gland and/or closing the pharyngotomy with a digastric muscle flap can help prevent fistula formation, although most fistulae are self-limited.

***Internal carotid artery injury:*** Preoperative cross-sectional imaging to evaluate the course of the ICA is important. The ICA typically lies 1.5-2.5cm lateral to the superior constrictor muscle, though 2-3% of patients can have a kinked, curling or otherwise tortuous ICA, increasing risk of injury. Preserving a thin layer of pharyngeal constrictor (depends on tumour extent), buccopharyngeal fascia and pharyngeal fat pad can decrease the risk of injury.

***Neural injury (lingual, XI, XII):*** The lingual nerve and lingual branches of the glossopharyngeal and hypoglossal nerves can be injured by surgical trauma, thermal injury, or by compression or traction of the retractor. Therefore, intermittently release suspension of the tongue, especially during parts of the procedure when it will not prolong the surgery, such as while awaiting the results of frozen pathology specimens.

- ***Glossopharyngeal nerve:*** Injury either directly, or by stretching or thermal injury can cause decreased taste and difficulty swallowing. It is at greatest risk during the inferolateral dissection of the glossotonsillar fossa as it pierces the superior constrictor.
- ***Hypoglossal nerve:*** Injury can have serious implications for speech and swallowing. While it is typically not encountered in an oropharyngeal resection, it is most at risk of direct or thermal injury as it passes superior to the hyoid bone and medial to the hyoglossus muscle.
- ***Lingual nerve*** compression or stretching by the retractor may cause dysgeusia, which is usually transient

**Oral cavity injury:** Accidental injury to oral cavity structures is always a concern during transoral surgery but is particularly true with robotic instrumentation. The console surgeon's field of view is restricted; therefore, it is incumbent on the surgical assistant to pay close attention to possible pressure or laceration injuries to the lips, teeth, and gums from the robotic arms. Standard dental guards may be employed, depending on the retractor used, or custom dental guards may be prefabricated or made from Aquaplast at the time of surgery. A generally rule is that if the robotic instruments cannot be seen with the robotic endoscope, they should not be moved with the robotic controls, but rather moved into the field of view by the assistant under direct vision.

#### ***Airway compromise***

- The ETT will invariably move in the operative field, and it is not always possible to prevent interference with the surgical instruments and the retractor
- One may need to retract or manipulate the ETT and accidentally cause extubation
- Another risk of the ETT transiting the operative field is the possibility for an **airway fire**. This is a greater risk when using alternate energy sources, such as CO<sub>2</sub> laser, and can be mitigated by using laser-safe tubes and maintaining the FiO<sub>2</sub> at <30%. It is important to discuss the immediate actions of all surgical team members if an airway fire should occur. Postoperative tongue and airway oedema can cause delayed airway compromise. Perioperative steroids may mitigate this, but delayed extubation or even prophylactic tracheostomy may be necessary if significant postoperative oedema is expected or does occur.
- Postoperative haemorrhage may also cause airway compromise.

#### **In summary**

TORS is a safe and oncologically effective treatment for selected oropharyngeal tumours. Appropriate patient selection, thorough case preparation, and a comprehensive understanding of surgical anatomy are essential to achieve optimal outcomes using this surgical tool.

#### **References**

1. Moore E and Van Abel K. Transoral Approaches to Malignant Neoplasms of the Oropharynx, in *Cummings Otolaryngology: Head and Neck Surgery*. 1423-43.e3
2. Timbang MR et al., HPV-related oropharyngeal cancer: a review on burden of the disease and opportunities for prevention and early detection. *Hum Vaccin Immunother*, 2019. 15(7-8): 1920-8
3. Wolf G et al. Induction chemotherapy plus radiation compared with surgery plus radiation in patients with advanced laryngeal cancer. *N Engl J Med*, 1991. 324(24):1685-90
4. Byrd J and Duvvuri U. Supraglottic Transoral Robotic Surgery, in *Operative Otolaryngology: Head and Neck Surgery*. 2008, Saunders/Elsevier: Philadelphia. p. 113-7
5. Dong Y, et al. Long-term toxicities in 10-year survivors of radiation treatment for head and neck cancer. *Oral Oncol*, 2017.71:122-8
6. Dong Y. et al., Incidence and outcomes of radiation-induced late cranial neuropathy in 10-year survivors of head and neck cancer. *Oral Oncol*, 2019. 95:59-64
7. Yeh D, et al., Transoral robotic surgery vs. radiotherapy for management of oropharyngeal squamous cell carcinoma - a systematic review of the literature. *Eur J Surg Oncol (EJSO)*, 2015. 41(12):1603-14

8. Chai R., O'Malley B, Newman J, Transoral Robotic Surgery for Neoplasms of the Base of Tongue, in *Operative Otolaryngology: Head and Neck Surgery*. 2008, Saunders/Elsevier: Philadelphia. p. 256-60
9. Gross, ND et al., Transoral Robotic Surgery, in *Atlas of Head and Neck Surgery*. 2011. p. 298-305
10. Kejner A and Newman J. Transoral and Robotic Tonsil Surgery for Cancers of the Base of the Tongue and Pharynx, in *Operative Otolaryngology: Head and Neck Surgery*. 2008, Saunders/ Elsevier: Philadelphia. p249-55
11. Shah J et al., Pharynx and Esophagus, in *Jatin Shah's Head and Neck Surgery and Oncology*. 2020, Elsevier/Mosby: Philadelphia. p299-364
12. Garas G and Arora A. Robotic Head and Neck Surgery: History, Technical Evolution and the Future. *ORL J Otorhinolaryngol Relat Spec*, 2018. 80(3-4):117-24
13. Gun R and Ozer E. Surgical anatomy of oropharynx and supraglottic larynx for transoral robotic surgery. *J Surg Oncol*, 2015. 112(7):690-6
14. Bollig CA, et al., Prophylactic arterial ligation following transoral robotic surgery: A systematic review and meta-analysis. *Head Neck*, 2020. 42(4):739-46
15. Stokes W, et al. Bleeding Complications After Transoral Robotic Surgery: A Meta-Analysis and Systematic Review. *The Laryngoscope*, 2021. 131(1): 95-105
16. Feng AL, et al. Feeding Tube Placement Following Transoral Robotic Surgery for Oropharyngeal Squamous Cell Carcinoma. *Otolaryngolog Head Neck Surg* 2021 Jun 22: Epub ahead of print

## Additional Open Access Resources

Transoral Robotic Surgery (TORS) - Setup and Basics:

<https://vula.uct.ac.za/access/content/group/ba5fb1bd-be95-48e5-81be-586fbaeba29d/Transoral%20Robotic%20Surgery%20TORS%20-%20Setup%20and%20Basics.pdf>

Transoral Robotic Surgical (TORS) approaches to Parapharyngeal Space, Hypopharynx and Larynx

<https://vula.uct.ac.za/access/content/group/ba5fb1bd-be95-48e5-81be-586fbaeba29d/Transoral%20Robotic%20Surgical%20TORS%20-%20approaches%20to%20Parapharyngeal%20Space%2C%20Hypopharynx%20and%20Larynx.pdf>

Transoral Robotic Thyroidectomy (TORT) and Robotic Facelift Thyroidectomy (RFT):

<https://vula.uct.ac.za/access/content/group/ba5fb1bd-be95-48e5-81be-586fbaeba29d/Transoral%20Robotic%20Thyroidectomy%20TORT%20and%20Robotic%20Facelift%20Thyroidectomy%20RFT.pdf>

AfHNS Oropharyngeal Cancer Clinical Practice Guideline:

<https://developingworldheadandneckcancerguidelines.com/index-page-oropharyngeal-cancers/>

Oropharyngeal cancer resection:

[https://vula.uct.ac.za/access/content/group/ba5fb1bd-be95-48e5-81be-586fbaeba29d/Oropharyngeal cancer resection.pdf](https://vula.uct.ac.za/access/content/group/ba5fb1bd-be95-48e5-81be-586fbaeba29d/Oropharyngeal%20cancer%20resection.pdf)

Resection cancers of base of tongue:

<https://vula.uct.ac.za/access/content/group/ba5fb1bd-be95-48e5-81be-586fbaeba29d/Resection%20of%20cancers%20of%20the%20base%20of%20tongue.pdf>

Transoral lateral oropharyngectomy (radical tonsillectomy) for cancer of the tonsil:

<https://vula.uct.ac.za/access/content/group/ba5fb1bd-be95-48e5-81be-586fbaeba29d/Transoral%20lateral%20oropharyngectomy%20radical%20tonsillectomy%20for%20cancer%20of%20the%20tonsil.pdf>

### Authors

Charles D Meyer MD  
Department of Otolaryngology - Head and Neck Surgery  
Naval Medical Center Portsmouth  
VA, USA

[chardmeyer@gmail.com](mailto:chardmeyer@gmail.com)

I am a military service member. This work was prepared as part of my official duties. Title 17 U.S.C. 105 provides that "Copyright protection under this title is not available for any work of the United States Government." Title 17 U.S.C. 101 defines a United States Government work as a work prepared by a military service member or employee of the United States Government as part of that person's official duties. The views expressed in this publication are those of the authors and do not necessarily reflect the official policy or position of the Department of the Navy, Department of Defence, or the United States Government.

Andrew R Larson MD  
Head and Neck Surgery/Microvascular Reconstruction  
Lahey Hospital and Medical Center  
Assistant Professor  
Boston University School of Medicine  
[andrewroch7@gmail.com](mailto:andrewroch7@gmail.com)

Jeremy D Richmon MD  
Ass Professor of Otolaryngology Head & Neck Surgery  
Massachusetts Eye and Ear  
Harvard University  
Boston, MA, USA  
[jeremy\\_richmon@meei.harvard.edu](mailto:jeremy_richmon@meei.harvard.edu)

Andrew J Holcomb, MD  
Head and Neck Surgeon  
Estabrook Cancer Center  
Methodist Hospital, Nebraska  
Assistant Professor  
Creighton University Dept of Surgery  
[andrewjholcomb@gmail.com](mailto:andrewjholcomb@gmail.com)

### Editor

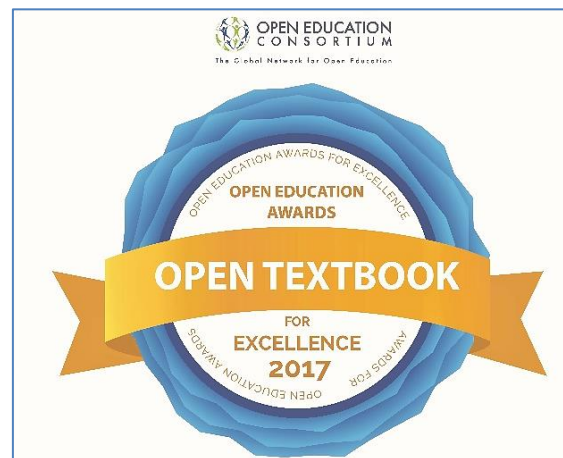
Johan Fagan MBChB, FCS (ORL), MMed  
Professor and Chairman  
Division of Otolaryngology  
University of Cape Town  
Cape Town, South Africa  
[johannes.fagan@uct.ac.za](mailto:johannes.fagan@uct.ac.za)

**THE OPEN ACCESS ATLAS OF  
OTOLARYNGOLOGY, HEAD &  
NECK OPERATIVE SURGERY**

[www.entdev.uct.ac.za](http://www.entdev.uct.ac.za)



The Open Access Atlas of Otolaryngology, Head & Neck Operative Surgery by [Johan Fagan \(Editor\)](mailto:johannes.fagan@uct.ac.za) [johannes.fagan@uct.ac.za](mailto:johannes.fagan@uct.ac.za) is licensed under a [Creative Commons Attribution - Non-Commercial 3.0 Unported License](https://creativecommons.org/licenses/by-nc/3.0/)



University of Cape Town  
Open Textbook Award



2020